

PennHIP Report

Referring Veterinarian: Dr Jessica Kirkpatrick Email: cvhbozeman@gmail.com	Clinic Name: Cottonwood Veterinary Hospital MT Clinic Address: 450 N. Cottonwood Rd. Bozeman, MT 59718 Phone: (406) 582-0555 Fax: (406) 582-4496
---	--

Patient Information

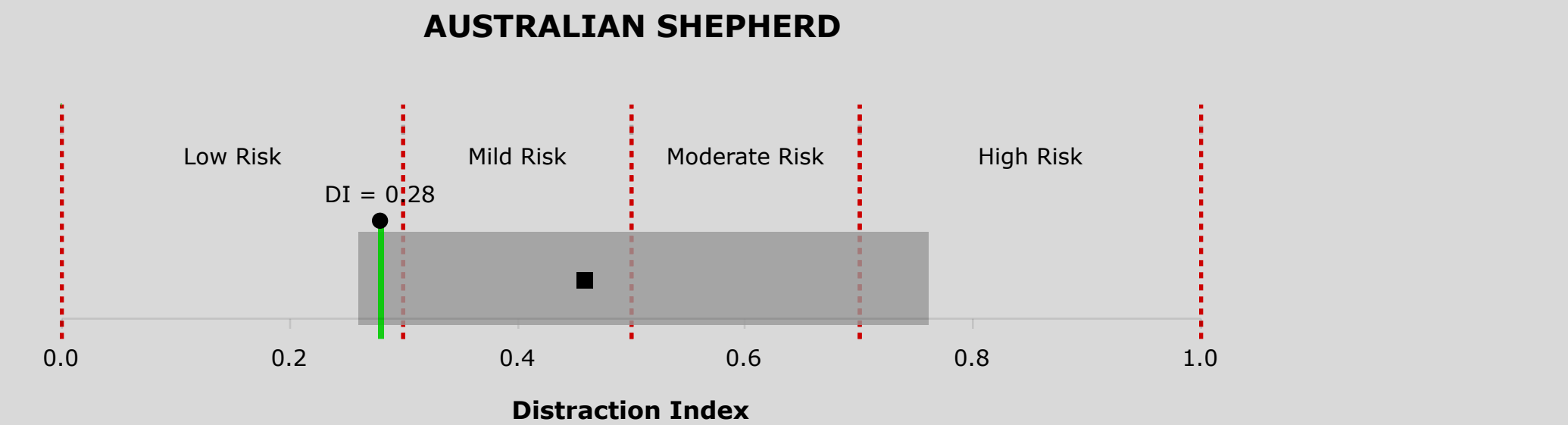
Client: Cooke,, Kelly Patient Name: Kody Reg. Name: PennHIP Num: 110158 Species: Canine Date of Birth: 25 Sep 2016 Sex: Male Date of Study: 31 Jul 2017 Date of Report: 09 Aug 2017	Tattoo Num: Patient ID: 7472 - Kody Registration Num: Microchip Num: Breed: AUSTRALIAN SHEPHERD Age: 10 months Weight: 45 lbs/20.4 kgs Date Submitted: 09 Aug 2017
---	---

Findings

Distraction Index (DI): Right DI = 0.28, Left DI = 0.28.
 Osteoarthritis (OA): **No radiographic evidence of OA for either hip.**
 Cavitation/Other Findings: No cavitation present.

Interpretation

Distraction Index (DI): The laxity ranking is based on the hip with the greater laxity (larger DI). In this case the DI used is 0.28.
 OA Risk Category: The DI is less than or equal to 0.30. This patient is at minimal risk for hip OA.
 Distraction Index Chart:



BREED STATISTICS: This interpretation is based on a cross-section of 1722 canine patients of the AUSTRALIAN SHEPHERD breed in the AIS PennHIP database. The gray strip represents the central 90% range of DIs (0.26 - 0.76) for the breed. The breed average DI is 0.46 (solid square). The patient DI is the solid circle (0.28).

SUMMARY: The degree of laxity (DI = 0.28) falls within the central 90% range of DIs for the breed. This amount of hip laxity places hip at a minimal risk to develop hip OA. **No radiographic evidence of OA for either hip.**